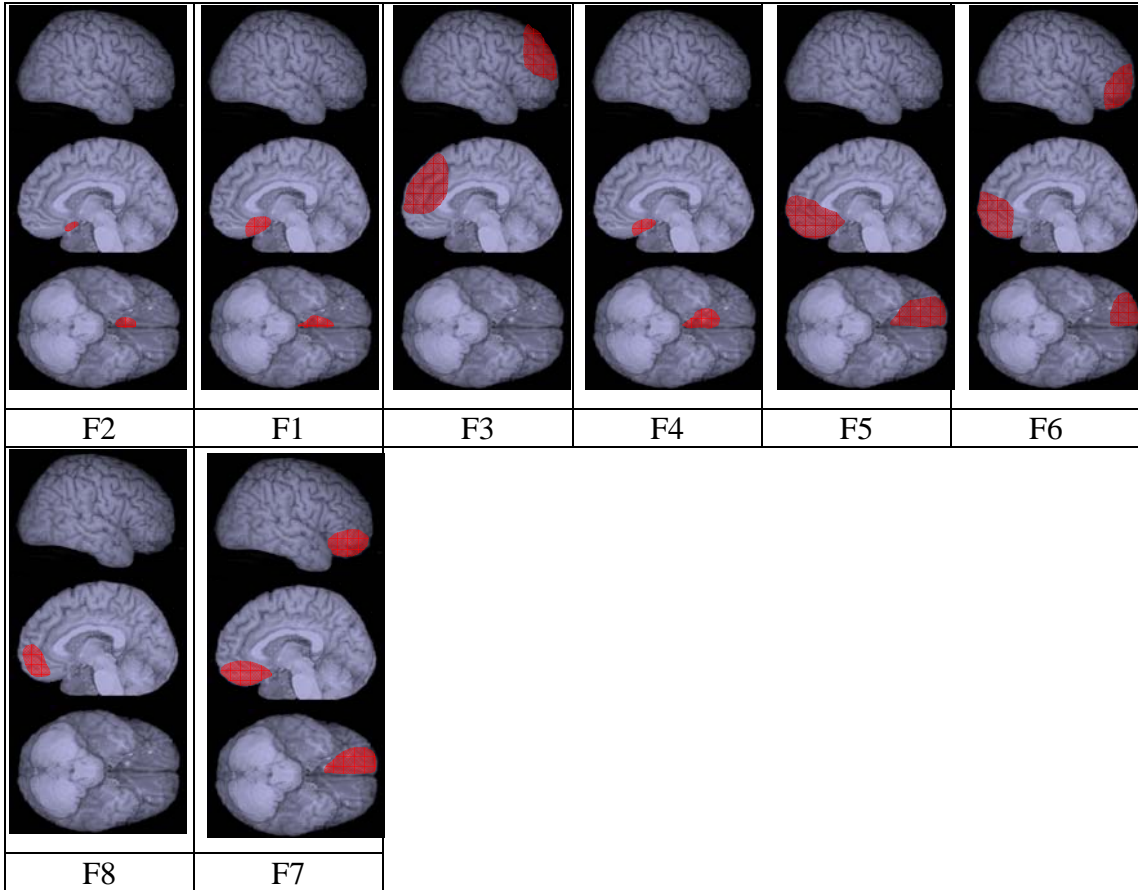


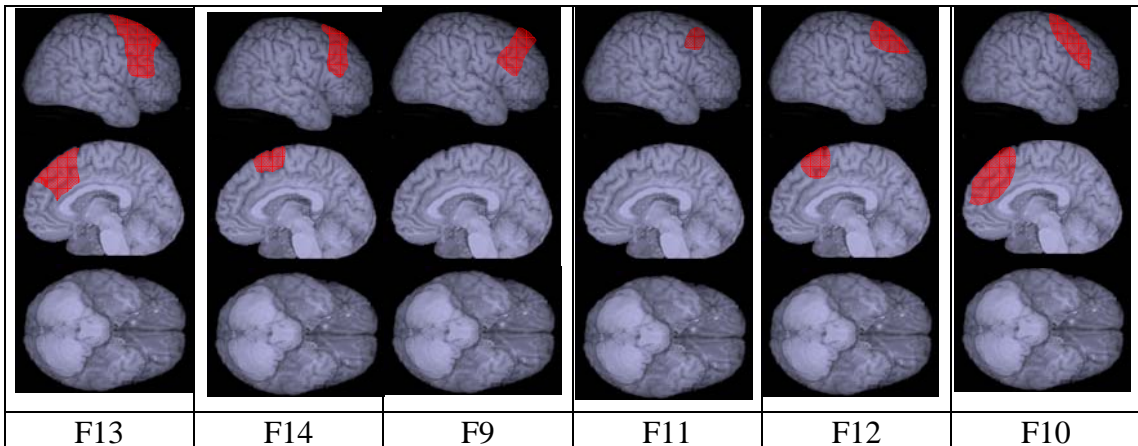
E-Figure1 : reconstructions of the lesions for each patient in the frontal damage groups.

Right prefrontal cortex lesions

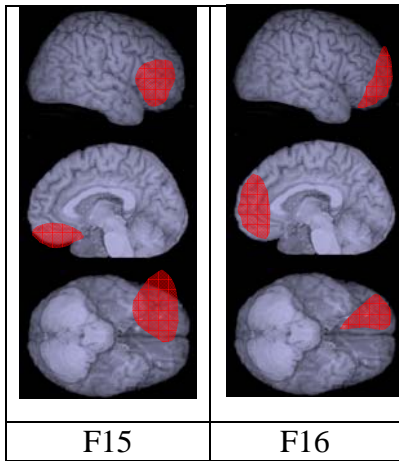
Ventromedial prefrontal lesions



Dorsolateral lesions

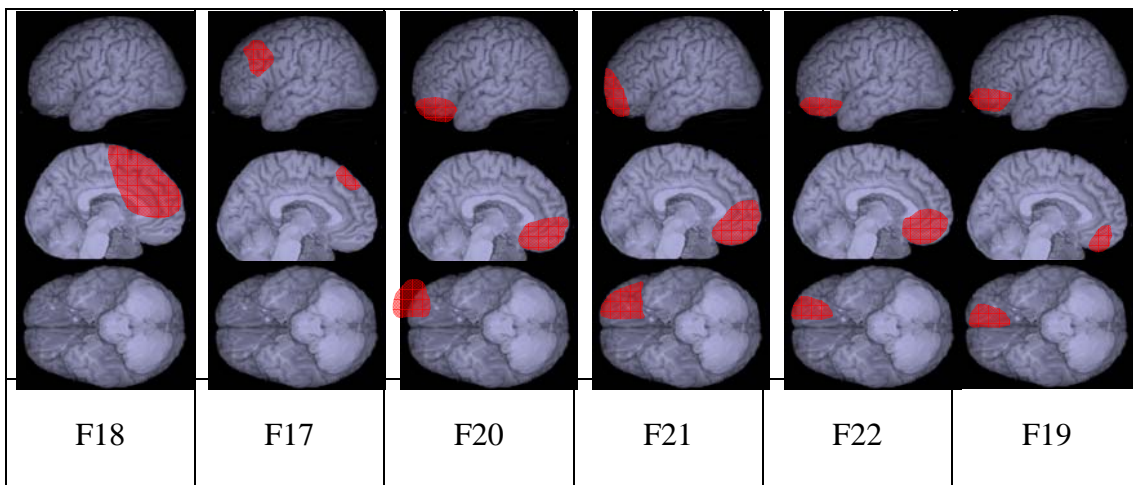


Right prefrontal cortex lesions: extensive lesions.

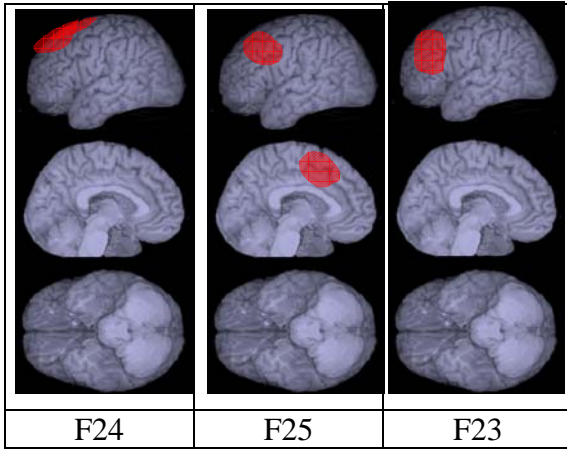


Left prefrontal cortex lesions

Ventromedial lesions



Left prefrontal cortex lesions: dorsolateral lesions



Extensive damage

